



Original

Free Access

Ultrasound-guided (USG) transversus abdominis plane (TAP) block with bupivacaine and dexmedetomidine on the control in postoperative analgesia of inguinal hernia surgery: A randomized clinical trial

Hossein Khoshrang¹, Hossein Hemmati², Mohammad Reza Habibi^{1*}, Mohaya Farzin³, Abbas Sedighi-Nejad⁴, Cyrus Emir Alavi⁵, Zahra Pourhabibi⁶

¹ Anesthesiology Research Center, Department of Anesthesiology, Alzahra Hospital, Guilan University of Medical Sciences, Rasht, Iran

² Department of Vascular Surgery, Razi Clinical Research Development Unit, Razi Hospital, Guilan University of Medical Sciences, Rasht, Iran

³ Department of physiology, Razi Clinical Research Development Unit, Razi Hospital, Guilan University of Medical Sciences, Rasht, Iran

⁴ Anesthesiology Research Center, Guilan University of Medical Sciences, Rasht, Iran

⁵ Department of Anesthesiology, Neuroscience Research Center, Avicenna University Hospital, Guilan University of Medical Sciences, Rasht, Iran

⁶ Razi Clinical Research Development Unit, Razi Hospital, Guilan University of Medical Sciences, Rasht, Iran

Abstract

Introduction: Transversus abdominis plane block (TAPB) is now a well-established technique in postoperative analgesia for lower abdominal surgeries. We aimed to investigate the effects of adding dexmedetomidine to bupivacaine used in USG (TAP block on postoperative pain and complications in patients undergoing inguinal hernia repair.

Materials and Methods: About 66 eligible patients enrolled in the survey. They were randomly assigned to one of the two groups of 20 CC of bupivacaine 0.5% + 1 CC Normal saline or 20 CC of bupivacaine 0.5% + 100µg dexmedetomidine. The amount of pethidine consumption, postoperative VAS score, and complications were measured. Patients were evaluated at the recovery ward (T0) and 2, 4, 6, 12, and 24 hours after surgery. Regarding the VAS score and if the patient's pain complained from a VAS \geq 3, pethidine 0.5 mg/kg was administered. The total dose, the average dose of pethidine used, and the first time of pethidine administration after the nerve block was recorded.

Results: Two groups had no significant difference regarding baseline characteristics. A significant difference was found at T4 about VAS (P=0.005). The amount of pethidine consumption was lower in the DEX group but not statistically significant except for T4 (P=0.006). The two groups showed no difference regarding side effects such as PONV.

Conclusion: Injection of dexmedetomidine in combination with bupivacaine for TAPB is an effective and safe drug for controlling pain after hernia surgery.

Keywords: Transversus abdominis plane block; Bupivacaine; Dexmedetomidine; Inguinal hernia

*Corresponding Author: Mohammad Reza Habibi

✉ Email: mohammadreza.habibi.md@gmail.com

Received: 2023.4.1, Accepted: 2023.6.19



OPEN ACCESS

Introduction

Hernia repair surgery is one of the most common surgeries in the world pain is one of the most common complications after hernia repair surgery. Chronic groin pain has been reported to be about 6-10% in long-term follow-up (1,2). There are several causes of postoperative pain. Include pain from incisions and deeper structures and emotional pain, such as pain when coughing and moving. However, the central pain is caused by an incision in the abdominal wall. Therefore, transversus abdominis muscle block for postoperative pain in lower abdominal surgery, including inguinal hernia, can be very effective, mainly when used as part of a multi-modal analgesic regimen (3). Some methods have been used to reduce postoperative pain. Drugs have been the gold standard for controlling severe pain for many years, but the side effects of these drugs have always posed challenges for physicians. These side effects include gastrointestinal motility disorders, urinary retention, constipation, respiratory depression, pruritus, abuse, postoperative vomiting nausea. Some other methods for postoperative pain control include using Nonsteroidal anti-inflammatory drugs (NSAIDs) and/or acetaminophen, gabapentin or pregabalin, I.V. ketamine, epidural with local anesthetic (with or without opioid), or intrathecal opioid, infusion of opioids with I.V. patient-controlled analgesia (PCA) (4).

Abdominis transversus muscle block has been used as an effective and safe method in providing balance analgesia after abdominal surgery. Rafi first did this block in 2001 (5). The abdominal transversus muscle block creates a sensory block through local anesthetic infiltration between the internal oblique and transverse abdominal muscles. In this block, three layers of muscle, external oblique, internal oblique, and transverse abdominal muscle, are anesthetized. Moreover, the T7–T12 intercostal muscles of the ilioinguinal nerve, the iliohypogastric nerve, the L1–L3 nerves, and the lateral branches of the cutaneous are blocked (6).

The blocking reduces the use of drugs after surgery, the time of the first request for pain relief, and the side effects of drugs. Among the available local anesthetic drugs, long-acting types such as bupivacaine are an

excellent choice. Bupivacaine is an amide local anesthetic used in many studies to block (7). To perform this block, using an ultrasound guide is more accurate and practical than blind methods (8,9). It also has fewer side effects because the location of the needle and local anesthetic propagation is entirely recognizable. However, performing this block without an ultrasound guide can rupture the intraperitoneal membrane (10).

On the other hand, in situations where only local anesthetics are used, one of the problems with the block is the limitation of analgesia time. Other drugs as a supplement to the block can increase the quality and time of the block effect and reduce their side effects by decreasing the dose. Studies have shown the addition of various drugs, including dexmedetomidine, morphine, sufentanil, clonidine, adrenaline, and magnesium sulfate (11). Dexmedetomidine has been proposed as an adjunct to local anesthetics. Many studies show that adding dexmedetomidine to local anesthetics increases the duration of action and analgesia time after surgery (12,13). It is a selective alpha two receptor agonist that acts by inhibiting these receptors in the central nervous system to inhibit the release of norepinephrine in a dose-dependent manner (14). It also reduces neuronal activity through inhibitory effects on sodium and potassium channels and exerts its analgesic role by inhibiting the transmission of neural messages in C-fibers. The combination of bupivacaine and dexmedetomidine has been used successfully in some other blocks (15,16).

Due to the importance of the issue and its application in improving the quality of life of patients, providing desirable medical services, and reducing hospitalization days and economic costs, we decided to conduct the present study with the aim of the effectiveness of TAPB with USG in reducing pain after inguinal hernia surgery in Razi Hospital, Rasht, Iran.

Materials and Methods

Study design and variables

This study was a controlled, randomized clinical trial with a double-blind, parallel design on patients who were candidates for elective inguinal hernia surgery. It was performed with an age range of 18 to 65 years and with ASA class I, II. After approving the draft study

and receiving the ethical code (IR.GUMS.REC.1397.449) and IRCT code (IRCT20121216011766N5), obtaining informed consent from eligible patients was included. In addition, all methods were performed following the Declaration of Helsinki, and all individuals consented to participate in this study. Patients who met the inclusion criteria were randomly assigned by one of the nurses of the relevant ward who was unaware of the study to two groups of 33 people with Intervention (I) and control (C) marks in intervention and control groups. Random sequences were generated using the Random Generator program. Based on the randomized block method, 15 blocks of size 4 with a ratio of 1 to 1 (as two groups I and C) and one block of six were generated for 66 patients. After generating the list, each person was assigned a unique code, and during the study, the person was identified with this code. All patients underwent general anesthesia, and the patient's vital signs, including heart rate, respiration rate, and blood pressure, were monitored and recorded. Immediately after the operation and before transferring the patient to the recovery unit, by placing the 15 MHz linear probe of the ultrasound device (Midray) in a transverse position, just above the iliac crest and in the maxillary line on the same side of the surgery, after finding the sheet between the internal oblique muscle and the abdominal transversus muscle using ultrasound, in the control group: 20cc of 0.5% bupivacaine with 1cc of normal saline, and intervention group: 20cc of 0.5% bupivacaine with 1cc (100 mcg) of dexmedetomidine were injected (brand name Precedex containing 200 mcg/2ml, manufacturer HOSPIRA reference manufacturer of USA).

In the post-anesthesia care unit (PACU), at intervals of 0, 2, 4, 6, 12, and 24 hours after surgery, pain intensity was measured in two groups by VAS by asking the patient to show their pain intensity on a 10 cm ruler. A score of zero was given for analgesia, and a score of 10 for maximum pain. During the 24 hours, the patients were hospitalized in the ward, 0.5 mg/kg of pethidine was prescribed if they needed analgesia (VAS>3). The total dose, the average dose of pethidine used, and the first time of pethidine administration after the nerve block was recorded. Complications such as nausea, dizziness, and vomiting in the two groups were evaluated. Inclusion criteria are age 18 to 65 years,

body mass index 18-35 kg/m², drug insensitivity, ASA Class I, II, no infection at the injection site, no alcohol and drug addiction, and type of surgery (Inguinal hernia repair without tension). Also, surgery lasting more than two hours, the need for other operations during inguinal hernia surgery, the requirement to receive drugs in recovery, excessive bleeding, recurrence of hernias, and the need for spinal anesthesia excluded patients from the study.

Statistical Analysis

The required sample size was calculated using G*Power © software version 3.1.0. About 26 patients in each group were estimated by assuming the test power of 80%, and the first type error was 0.05 to determine the effect size of 0.8 (17). Finally, 33 patients in each group were determined by considering the 20% drop coefficient. The SPSS software version 18 was used for all statistical analyses. Fisher and Chi-square tests were used to compare the ratios in the two groups. Also, to compare the quantitative means in the two groups, the Mann-Whitney U test, and to compare the analgesia time, Kaplan-Meier and TaroneWare tests were used. Generalized Linear Models (GLM) and Generalized Estimating Equation (GEE) were used to investigate the effect of drugs on VAS scores during the study period. A value of P< 0.05 was considered statistically significant

Results

Demographic characteristics of patients undergoing inguinal hernia surgery in two groups affected by bupivacaine injection and combined with dexmedetomidine via TAP block with ultrasound guide were examined by chi-square test, which the results are shown in Table 1. It was also found that in the C group, there was a statistically significant difference between the values of VAS in the periods studied (P<0.001). Also, there is a statistically significant difference between the two groups between VAS values in the studied periods (P=0.047). As shown in Table 2, intergroup statistical estimation illustrated that there was a statistically significant difference between the amounts of pethidine intake in bupivacaine+dexmedetomidine (F=44.86, P<0.001) and bupivacaine groups (F=28.6, P<0.001). A significant difference was also found in the statistical

estimation between groups ($F=3.89$, $P<0.001$) according to the period. The comparison between the mean of pethidine intake among two groups with (45.3

± 29.47) and without (60.0 ± 37.79) dexmedetomidine was not statistically significant ($P=0.094$).

Table 1. Demographic characteristics of patients undergoing inguinal hernia surgery in two groups through TAP block with ultrasound guide.

Variable	Bupivacaine+Dexmedetomidine		Bupivacaine		Total		P-Value
		n (%)		n (%)		n (%)	
Age (year)	> 40	7 (21.2)		9 (27.3)		16 (24.2)	0.015
	41-60	26 (78.8)		21 (63.6)		47 (71.2)	
	>60	0 (0.0)		3 (9.1)		3 (4.5)	
Mean \pm SD	Age (year)	8.3 \pm 8.3		48.24 \pm 10.51		47.81 \pm 9.41	0.717
ASA class	I	27 (81.8)		23 (69.7)		50 (75.8)	0.251
	II	6 (18.2)		10 (30.3)		16 (24.2)	
Mean \pm SD	Weight (kg)	69.93 \pm 5		67.9 \pm 5.02		68.92 \pm 5.08	0.105

Table 2. Evaluation of changes in pethidine intake (mg) and comparison of mean pethidine in patients undergoing inguinal hernia surgery in two groups via TAP block.

Time	Bupivacaine + Dexmedetomidine	Bupivacaine	P-Value
Recovery	22.27 \pm 16.1	23.78 \pm 14.94	0.693
2 hours after surgery	21.06 \pm 16.28	21.21 \pm 16.39	0.97
4 hours after surgery	1.96 \pm 7.89	11.06 \pm 15.94	0.005
6 hours after surgery	0 \pm 0	2.87 \pm 9.27	0.079
12 hours after surgery	0 \pm 0	1.06 \pm 6.09	0.321
24 hours after surgery	0 \pm 0	0 \pm 0	-

Moreover, the comparison of mean pethidine in patients in these two groups was shown that no significant differences were found between the amounts of pethidine intake ($P=0.094$) (Figure 1).

According to the information shown in Figure 2, using a t-test, it was found that only 4 hours after surgery, there was a statistically significant difference between the amounts of pethidine in the two groups ($P=0.005$). According to Mann-Whitney U test results in Table 3, a significant difference was not observed between the values of analgesia duration (hours) in patients in two groups 24 hours after surgery ($P=0.567$).

Table 3. Comparison of analgesia duration in patients undergoing inguinal hernia surgery in two groups through TAP block in 24 hours after surgery.

Group	Number	Mean \pm SD	P-Value
Bupivacaine + Dexmedetomidine	33	6 \pm 10.35	0.567
Bupivacaine	33	4.54 \pm 9.33	

Based on Chi-square test results, table 4, a statistically significant relationship was not observed between the incidence of side effects (nausea or vomiting, or dizziness) in the two groups 24 hours after surgery ($P=0.459$).

Table 4. Evaluation of side effects (nausea or vomiting) in patients undergoing inguinal hernia surgery in two groups.

Side effects	Bupivacaine +Dexmedetomidine		Bupivacaine		Total		P-Value
		n (%)		n (%)		n (%)	
+		16 (48.5)		19 (57.6)		35 (53.0)	0.459
-		17 (51.5)		14 (42.4)		31 (47.0)	
Total		33 (100)		33 (100)		66 (100)	

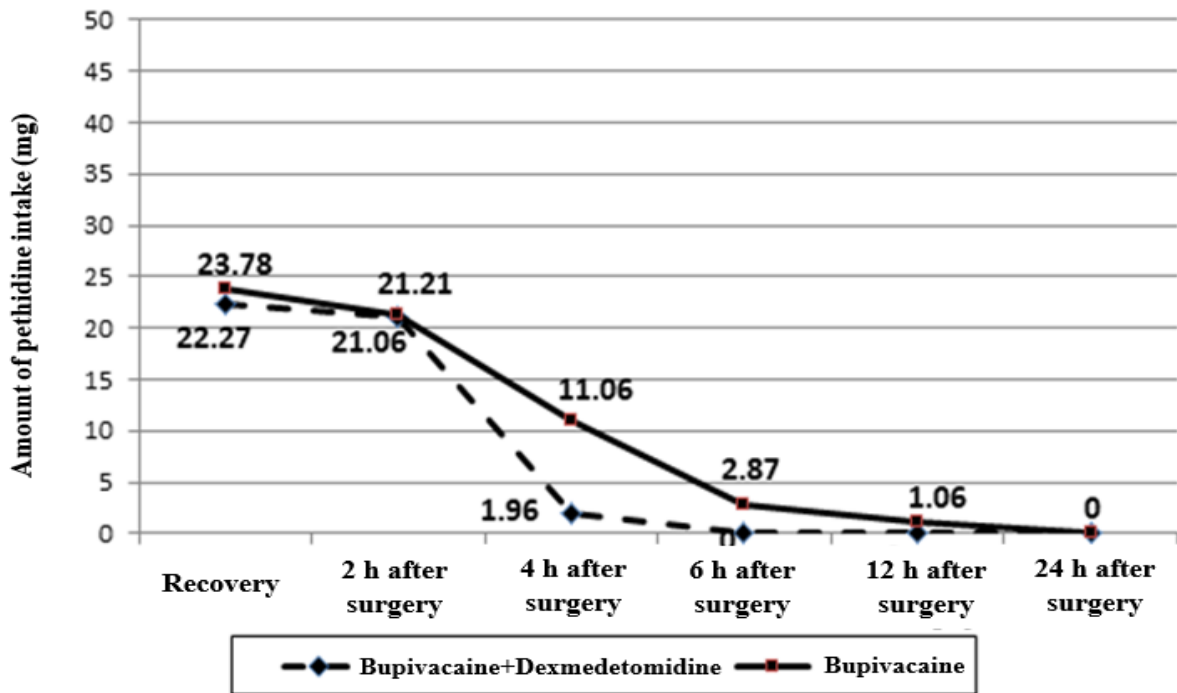


Figure 1. Evaluation of changes in pethidine intake in patients undergoing inguinal hernia surgery in two groups under the influence of bupivacaine injection alone and in combination with dexmedetomidine via TAP block.

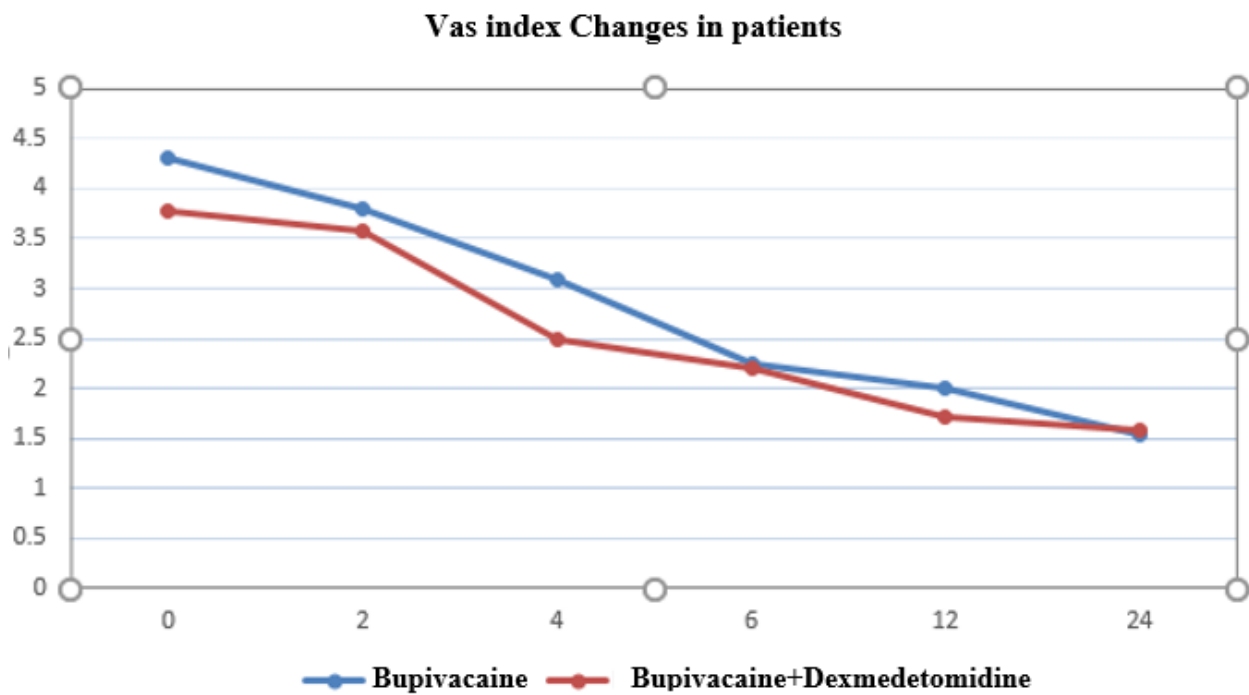


Figure 2. Evaluation of VAS index changes in patients undergoing inguinal hernia surgery in two groups via TAP.

Discussion

Acute postoperative pain strongly predicted persistent pain following both open anterior and endo-laparoscopic hernia repair (18). Physiological responses to surgical pain and trauma include respiratory effects, cardiovascular, Gastrointestinal, urinary system, neuroendocrine, and metabolic, which lead to side effects. Control of physiological processes associated with acute postoperative pain can lead to satisfaction and increase the quality of life in patients (19). Kokoulu et al. described the block as an effective and cost-effective method. Their study reported significantly lower levels of anesthetic drugs in the group that underwent this block than in the group undergoing standard general anesthesia and laparoscopic inguinal hernia surgery (20).

Various methods have been proposed to control acute pain after surgery, including administering nonsteroidal anti-inflammatory drugs, peripheral nerve block, and nerve root block (21). Increasing awareness of drug-related side effects, including respiratory depression, obstruction, and sedation, has led to a shift in drug use to control postoperative pain (22). TAP block has been used as an effective and safe method in providing balance analgesia after abdominal surgery by blocking the abdominal wall nerve. In the USG method, local anesthetics are injected near the nerve and help increase the injection's accuracy (23). Various studies have shown that TAP block is an effective technique for controlling pain and reducing morphine use after surgery, including retropubic prostatectomy, colorectal surgery, a cesarean delivery, abdominal hysterectomy, laparoscopic appendectomy, and abdominal hernia surgery (23–26).

This study evaluated the effectiveness of TAP block with USG in reducing pain after inguinal hernia surgery. It showed that the pain intensity in the two groups significantly differed in the first four hours after surgery. No significant difference in hemodynamic changes (H.R., MAP) was observed in any of the cases during surgery. During the first four hours after surgery, a significant difference was observed between the two groups regarding pethidine consumption. However, in the following hours, between 4 and 12 hours, the amount of pethidine in the two groups was not significantly different. In addition, there was no

significant difference between the two groups regarding postoperative side effects.

According to other studies, analgesia time with bupivacaine block is about 4-6 hours. Therefore, the results of this study can be justified that in the first 4 hours, no significant difference was observed between the two groups in terms of VAS score. However, after this time and with the disappearance of bupivacaine effects, the effectiveness of dexmedetomidine increased block efficiency. Furthermore, Aksu et al. reported the satisfaction of patients who have undergone abdominal surgery (26). Therefore, the results of this study are consistent with the present study and suggest that dexmedetomidine is a drug whose addition to bupivacaine in TAP block reduces pain and drug use after surgery. It should be noted that the dose of drugs used in the two studies is the same.

In the study of Feyz et al., the pain of patients in resting and moving positions in the ilioinguinal/iliohypogastric group was less than the TAP block group, which was statistically significant. Besides, satisfaction with analgesia was significantly higher in the ilioinguinal/iliohypogastric group than in the TAP block group. Therefore, it was suggested that the iliohypogastric ultrasound-guided block is more suitable than the TAP block; and to control pain after inguinal hernia surgery, the ultrasound-guided ilioinguinal /iliohypogastric block is more appropriate than the TAP block (27). In the current study, superiority was not observed for the TAP block, which can be justified due to the difference in the method of the present study with this study, which used bupivacaine alone. Due to the high prevalence of this operation and its increasing importance in controlling acute pain after surgery is a topic that requires extensive research.

Limitations

Since the characteristics of people and their interpretation of pain intensity, their expectation of pain, and their level of tolerance are different and can be effective in expressing pain by the patient; it is challenging to assess patients' pain. Furthermore, due to the limited follow-up times, the evaluation of patients was limited in terms of possible complications and the procedure's effectiveness.

Conclusions

According to the results of this study, injection of dexmedetomidine in combination with bupivacaine for TAPB can be used as an effective and safe drug for controlling pain after hernia surgery.

Author contribution

HKH and **HH** researched literature and conceived the study. **CEA** and **ZP** were involved in protocol development, gaining ethical approval, patient recruitment and data analysis. **MF**, **MRH** and **ASN** wrote the first draft of the manuscript. All authors reviewed and edited the manuscript and approved the final version of the manuscript

Conflict of interest

The authors reported no potential conflict of interest.

Ethics approval

This study was approved by the ethical committee at the Guilan University of Medical Sciences [I.R.GUMS.REC.1397.449].

Funding

There is no funding.

References

1. Takebayashi K, Matsumura M, Kawai Y, Hoashi T, Katsura N, Fukuda S, et al. Efficacy of transversus abdominis plane block and rectus sheath block in laparoscopic inguinal hernia surgery. *Int Surg*. April 2015;100(4):666–71.
2. Eklund A, Montgomery A, Bergkvist L, Rudberg C. Chronic pain 5 years after randomized comparison of laparoscopic and Lichtenstein inguinal hernia repair. *Br J Surg*. April 2010;97(4):600–8.
3. Hutchins J, Delaney D, Vogel RI, Ghebre RG, Downs LSJ, Carson L, et al. Ultrasound guided subcostal transversus abdominis plane (TAP) infiltration with liposomal bupivacaine for patients undergoing robotic assisted hysterectomy: A prospective randomized controlled study. *Gynecol Oncol*. September 2015;138(3):609–13.
4. Chou R, Gordon DB, de Leon-Casasola OA, Rosenberg JM, Bickler S, Brennan T, et al. Management of Postoperative Pain: A Clinical Practice Guideline From the American Pain Society, the American Society of Regional Anesthesia and Pain Medicine, and the American Society of Anesthesiologists' Committee on Regional Anesthesia, Executive Committee, and Administrative Council. *J pain*. February 2016;17(2):131–57.
5. Tran DQ, Bravo D, Leurcharusmee P, Neal JM. Transversus Abdominis Plane Block: A Narrative Review. *Anesthesiology*. November 2019;131(5):1166–90.
6. Raof RA, El Metainy SA, Alia DA, Wahab MA. Dexmedetomidine decreases the required amount of bupivacaine for ultrasound-guided transversus abdominis plane block in pediatrics patients: a randomized study. *J Clin Anesth*. February 2017;37:55–60.
7. Balakrishnan K, Ebenezer V, Dakir A, Kumar S, Prakash D. Bupivacaine versus lignocaine as the choice of local anesthetic agent for impacted third molar surgery a review. *J Pharm Bioallied Sci*. April 2015;7(Suppl 1):S230-3.
8. Fang WH, Chen XT, Vangsness CTJ. Ultrasound-Guided Knee Injections Are More Accurate Than Blind Injections: A Systematic Review of Randomized Controlled Trials. *Arthrosc Sport Med Rehabil*. August 2021;3(4):e1177–87.
9. McDermott G, Korba E, Mata U, Jaigirdar M, Narayanan N, Boylan J, et al. Should we stop doing blind transversus abdominis plane blocks? *Br J Anaesth*. Maart 2012;108(3):499–502.
10. Eslamian L, Kabiri-Nasab M, Agha-Husseini M, Azimaraghi O, Barzin G, Movafegh A. Adding Sufentanil to TAP Block Hyperbaric Bupivacaine Decreases Post-Cesarean Delivery Morphine Consumption. *Acta Med Iran*. Maart 2016;54(3):185–90.
11. Rana S, Verma RK, Singh J, Chaudhary SK, Chandel A. Magnesium sulphate as an adjuvant to bupivacaine in ultrasound-guided transversus abdominis plane block in patients scheduled for total

abdominal hysterectomy under subarachnoid block. *Indian J Anaesth.* Maart 2016;60(3):174–9.

12. Ding W, Li W, Zeng X, Li J, Jiang J, Guo C, et al. Effect of Adding Dexmedetomidine to Ropivacaine on Ultrasound-Guided Dual Transversus Abdominis Plane Block after Gastrectomy. *J Gastrointest Surg Off J Soc Surg Aliment Tract.* Junie 2017;21(6):936–46.

13. Fritsch G, Danninger T, Allerberger K, Tsodikov A, Felder TK, Kapeller M, et al. Dexmedetomidine added to ropivacaine extends the duration of interscalene brachial plexus blocks for elective shoulder surgery when compared with ropivacaine alone: a single-center, prospective, triple-blind, randomized controlled trial. *Reg Anesth Pain Med.* 2014;39(1):37–47.

14. Knezevic NN, Anantamongkol U, Candido KD. Perineural dexamethasone added to local anesthesia for brachial plexus block improves pain but delays block onset and motor blockade recovery. *Pain Physician.* 2015;18(1):1–14.

15. Tsantoulas C, McMahon SB. Opening paths to novel analgesics: the role of potassium channels in chronic pain. *Trends Neurosci.* Maart 2014;37(3):146–58.

16. Sun Q, Liu S, Wu H, Ma H, Liu W, Fang M, et al. Dexmedetomidine as an Adjuvant to Local Anesthetics in Transversus Abdominis Plane Block: A Systematic Review and Meta-analysis. *Clin J Pain.* April 2019;35(4):375–84.

17. Hotujec BT, Spencer RJ, Donnelly MJ, Bruggink SM, Rose SL, Al-Niimi A, et al. Transversus abdominis plane block in robotic gynecologic oncology: a randomized, placebo-controlled trial. *Gynecol Oncol.* Maart 2015;136(3):460–5.

18. Olsson A, Sandblom G, Franneby U, Sondén A, Gunnarsson U, Dahlstrand U. Do postoperative complications correlate to chronic pain following inguinal hernia repair? A prospective cohort study from the Swedish Hernia Register. *Hernia.* Februarie 2023;27(1):21–9.

19. Gousheh MR, Pipelzadeh MR, Akhondzadeh MR, Olapour AR, Alizadeh Z, Sahafi SA.

Intraoperative Administration of Magnesium Sulfate on Postoperative Pain of Inguinal Herniorrhaphy under General Anesthesia. *Armaghane Danesh.* 2013;18(6):420–9.

20. Kokulu S, Bakı ED, Kaçar E, Bal A, Şenay H, Üstün KD, et al. Effect of transversus abdominis plane block on cost of laparoscopic cholecystectomy anesthesia. *Med Sci Monit Int Med J Exp Clin Res.* Desember 2014;20:2783–7.

21. Soleimani S, Saghafinia M, Panahi Y, Madani SJ. Designing an evidence-based guideline for acute pain management in orthopedic surgeries. *Anesthesiol Pain.* 2014;5(2):10–8.

22. Soliz JM, Lipski I, Hancher-Hodges S, Speer BB, Popat K. Subcostal transverse abdominis plane block for acute pain management: a review. *Anesthesiol Pain Med.* 2017;7(5).

23. Tsai H-C, Yoshida T, Chuang T-Y, Yang S-F, Chang C-C, Yao H-Y, et al. Transversus abdominis plane block: an updated review of anatomy and techniques. *Biomed Res Int.* 2017;2017.

24. Elkassabany N, Ahmed M, Malkowicz SB, Heitjan DF, Isserman JA, Ochroch EA. Comparison between the analgesic efficacy of transversus abdominis plane (TAP) block and placebo in open retropubic radical prostatectomy: a prospective, randomized, double-blinded study. *J Clin Anesth.* September 2013;25(6):459–65.

25. Favuzza J, Delaney CP. Laparoscopic-guided transversus abdominis plane block for colorectal surgery. *Dis Colon Rectum.* Maart 2013;56(3):389–91.

26. Mankikar MG, Sardesai SP, Ghodki PS. Ultrasound-guided transversus abdominis plane block for postoperative analgesia in patients undergoing caesarean section. *Indian J Anaesth.* April 2016;60(4):253–7.

27. Faiz SHR, Nader ND, Niknejadi S, Davari-Farid S, Hobika GG, Rahimzadeh P. A clinical trial comparing ultrasound-guided ilioinguinal/iliohypogastric nerve block to transversus abdominis plane block for analgesia following open inguinal hernia repair. *J Pain Res.* 2019;12:201–7.