



## Giant cell tumor of the breast masquerading as a malignant breast tumor: a case report

Puja Bhavesh Jarwani <sup>1</sup>\*, Virat Rameshbhai Patel <sup>2</sup>, Raval Ravinderkumar Chhabra <sup>1</sup>, Vidhyasagar Sharma <sup>2</sup>, Anupama Raval <sup>1</sup>

<sup>1</sup> Department of Pathology, GCSMCH & RC, India

<sup>2</sup> Department of Surgery, GCSMCH & RC, India

### Abstract

**Introduction:** Giant cell tumours of the soft tissue (GCT-ST) are usually found in the superficial and deep soft tissues of the extremities but have been described in the pancreas, lung, thyroid gland, urothelial tract, skin, larynx, heart and very rarely, in the breast. At present, according to the World Health Organization's classification of soft tissue tumors, GCT-ST is categorized as an intermediate grade (rarely metastasizing) fibrohistiocytic tumour. GCT of the breast is extremely rare and to date, only eleven cases have been reported. We report a case of GCT of the breast, which was clinically suspected as a malignant tumor and discuss the different treatment modalities with the importance of close follow-up of the same after a thorough review of the literature.

**Case Presentation:** We report a case of a 45-year-old woman who noticed a tender lump in her left breast. A malignant tumour was suspected on clinical examination and imaging. Histological evaluation revealed a tumour composed of a mixture of round and oval mononuclear cells with minimal atypia and uniformly distributed multinucleated osteoclast-like giant cells (OGCs) with a stroma rich in blood vessels. IHC was done in which the OGCs stained positively for CD68 and CD45, mononuclear stromal cells were positive for vimentin whereas the tumour was negative for breast markers Progesterone Receptor (PR), Estrogen Receptor (ER), GATA 3, epithelial marker EMA, S-100 and Desmin; hence the definitive diagnosis of GCT of the breast was made.

**Discussion:** GCT of the breast, due to its rareness and the malignant-mimicking clinical presentation, causes difficulty in diagnosis. Other giant cell-rich lesions including breast cancer with OGCs, pleomorphic leiomyosarcoma, osteosarcoma, undifferentiated pleomorphic sarcoma and metastatic GCT-B are to be considered in the differential diagnosis.

**Conclusion:** GCT of the breast is an extremely rare tumour and pretends a breast malignant tumours. For the correct diagnosis of this rare tumour, combining the results of histological and immunohistochemical analyses helps in ruling out differential diagnosis

**Keywords:** Giant cell tumor, Osteoclastic giant cells, Breast, Immunohistochemistry

**Corresponding Authors:** Puja Bhavesh Jarwani

✉ Email: [pujarwani@gmail.com](mailto:pujarwani@gmail.com)

Received: 2023.5.24, Accepted: 2023.9.23



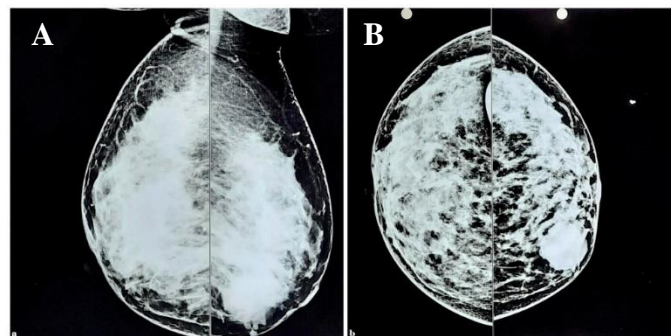
## Introduction

Giant cell tumour of soft tissue (GCT-ST) is uncommon and only a few cases are reported in the medical literature. In 1972, Slam and Sissons first reported 10 cases of a type of tumour that originated in the soft tissue but resembled Giant cell tumour of the bone (GCT-B) in morphology and considered it benign (1). Most GCT-ST follow a benign clinical course, sometimes locally aggressive, and rarely metastasize. At present, according to World Health Organization classification of soft tissues, GCT-ST is categorized as intermediate grade (rarely metastasising) Fibrohistiocytic tumour (2). The histiocytic component is non-neoplastic; however, they contributes significantly to the development of the lesion. Although GCT-ST is histologically similar to GCT-B it has been reported that > 90% of GCT-Bs have a driver mutation in the H3F3A gene, which makes it distinct from GCT-ST (3). GCT-ST are usually found in the superficial and deep soft tissues of the extremities but have been described in the pancreas, lung, thyroid gland, urothelial tract, skin, larynx, heart and very rarely, in the breast (4). After a comprehensive search of the literature, we could find only eleven cases of GCT-ST occurring in the breast to date (5-8). Although GCT-ST is usually considered as an intermediate-grade tumour, the prognosis is uncertain, and the standard therapy for the GCT of the breast has not been established (9). We report a case of GCT of the breast, which was clinically suspected as a malignant tumor and discuss the different treatment modalities with the importance of close follow-up of the same after a thorough review of the literature.

## Case report

A 45-year-old married woman was referred to the General Surgery Department after she noticed a painful lump in her left breast. The patient had no history of trauma, no significant family history and had achieved menarche at the age of 14 with regular menstrual cycle of 3-4 days. Obstetric History: G4P4A3L1. Physical examination revealed a 4 x 4 cm hard, painful lump in the upper inner quadrant of the left breast. The contralateral breast was unremarkable. There was no palpable axillary, supraclavicular or infraclavicular lymph node. Malignancy was strongly suspected on

clinical examination. Ultrasound showed approximately 30 x 25 mm sized well defined mixed echogenic lesion with internal cystic areas in upper inner quadrant at 9'o clock position in left breast. Mammography indicated a hyperdense BIRAD- IV lesion (suspicious for malignancy) (Figure 1).



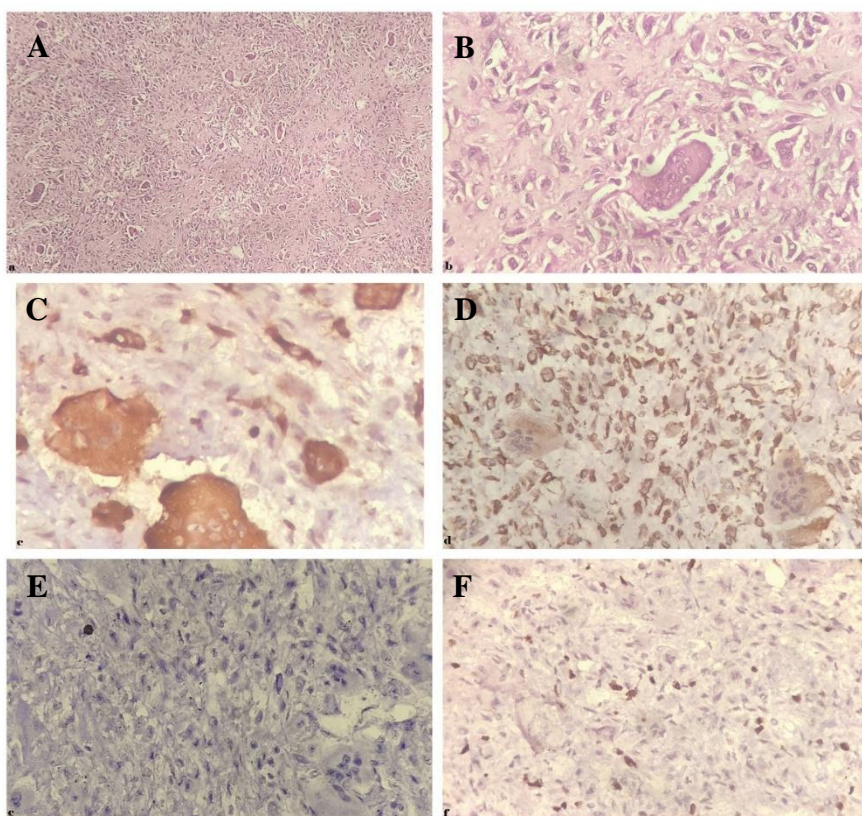
**Figure 1.** Mammography of Bilateral Breasts showing a hyperdense BIRADS IV lesion, suspicious for malignancy. **A.** Mediolateral view, **B.** Craniocaudal view.

Fine needle aspiration cytology (FNAC) correlation was advised. FNAC examination showed numerous multinucleated giant cells with foci of stromal cells and was suggestive of Giant cell-rich fibroepithelial lesion. Trucut biopsy from the lesion showed numerous multinucleated giant cells with stroma showing minimal atypia and low mitoses. No ductal element was seen. Findings were suggestive of Giant cell rich stromal lesion. Excision of the lesion was performed and sent for histopathological examination. Gross examination showed the presence of breast tissue with tumour total measuring 7.5x6.2x2.5cm. The outer surface was smooth, multilobulated and covered with fibro fatty tissue. On cutting, there was the presence of one well-circumscribed, solid cystic tumour measuring 6.0x4.0x2.0cm. The Cut surface showed a firm greyish-white solid area measuring 4.0x2.5x1.3cm along with a few hemorrhagic and cystic areas.

Histological evaluation of the tumour revealed a mixture of round to oval mononuclear stromal cells with minimal atypia and uniformly distributed multinucleated osteoclast-like giant cells (OGCs). Stroma was rich in blood vessels and showed marked hyalinization along with focal metaplastic bone formation. Surrounding breast parenchyma showed fibrocystic changes. There was no evidence of granuloma formation.

(Figure 2A: H& E stain, x100. The tumour revealed a mixture of round and oval mononuclear cells and uniformly distributed multinucleated osteoclast-like giant cells and Figure 2B: H& E stain, x400. Mononuclear stromal cells show minimal atypia and scanty mitoses). For further evaluation, sections were subjected to immunohistochemistry examination (IHC). The giant cell component of the tumour showed a strong positive reaction to histiocytic marker CD68 (Figure. 2C: IHC stain for CD68, x400. Osteoclastic giant cells stained positive for CD68). They also gave a positive reaction to leucocyte common antigen CD45. The stromal mononuclear component was stained positive for mesenchymal marker vimentin (Figure. 2D: IHC stain for Vimentin, x400. Mononuclear stromal cells stained positive for vimentin). The tumour was negative for breast markers like Progesterone Receptor (PR), Estrogen Receptor (ER) and GATA 3

along with Epithelial membrane antigen (EMA) (Figure. 2E: IHC stain for EMA, x400. Tumor cells negative for EMA). These findings along with relatively homogeneous bland-appearing features throughout the whole tumour ruled out breast cancer with OGCs. Lack of pleomorphic cells and IHC negative for Desmin ruled out pleomorphic leiomyosarcoma. The absence of sarcomatous features and malignant osteoid formation ruled out osteosarcoma. Although the tumour cells were positive for vimentin and negative for EMA, S-100 and Desmin, the absence of pleomorphic spindle cells and atypical mitoses ruled out the diagnosis of undifferentiated pleomorphic sarcoma. As there was no history of GCT of the bone, metastatic GCT of the bone was ruled out. The Ki-67 proliferation index was 20-25% in the stromal cells (Figure. 2F: IHC stain for Ki-67, x400. Ki-67 was positive in 20-25% of stromal tumor cells).



**Figure 2.** A. H& E stain, x100. The tumour revealed a mixture of round and oval mononuclear cells and uniformly distributed multinucleated osteoclast-like giant cells. B. H& E stain, x400. Mononuclear stromal cells show minimal atypia and scanty mitoses. C. IHC stain for CD68, x400. Osteoclastic giant cells stained positive for CD68. D. IHC stain for Vimentin, x400. Mononuclear stromal cells are positive for vimentin. E. IHC stain for EMA, x400. Tumor cells negative for EMA. F. IHC stain for Ki-67, x400. Ki-67 was positive in 20-25% of tumor cells.

The final diagnosis of Intermediate grade GCT-ST, Not Otherwise Specified was given and close follow-up was advised. The patient received no adjuvant therapy as GCT-ST is an intermediate-grade tumour. The patient was followed up post-operatively for nine months with regular clinical examination without any evidence of recurrence or metastasis.

## Discussion

We report a rare case of GCT of the breast, which due to its rareness and the malignant-mimicking clinical presentation, causes difficulty in diagnosis. Other giant cell-rich lesions including breast cancer with OGCs, pleomorphic leiomyosarcoma, osteosarcoma,



undifferentiated pleomorphic sarcoma and metastatic GCT-B were considered in the differential diagnosis. Primary invasive ductal carcinoma with OGCs is uncommon comprising less than 2% of breast carcinoma cases and rare subtype of metaplastic carcinoma with OGCs, comprising 11% of metaplastic carcinoma, should be differentiated from primary GCT-ST of the breast (10-11). A lack of epithelial component marked cellular atypia, and pleomorphism

along with IHC findings differentiates GCT from these tumours.

GCT-ST is an intermediate grade tumour which may recur locally but seldom metastasizes. As GCT of the breast can be potentially recurrent, inadequate resection can cause a local recurrence. We compared the findings of the present case with a few previously reported cases, the findings of which are as below (Table 1).

**Table 1.** Comparison of the present case with few others previously reported cases.

Study	Age / Sex	Laterality	Tumor size (cm)	Symptoms	Site	Imaging	Preoperative Diagnosis	Treatment	Follow up
<b>Present case</b>	45/F	Left	4	Tender mass in breast	Upper inner quadrant	Hyperdense lesion	Giant cell-rich stromal lesion	Excisional biopsy	9 months, no recurrence
<b>Luangxay T et al (5)</b>	59/F	Left	3	Non tender mass in breast	Retroareolar region	Microlobulated mass	Intracystic carcinoma	TM+SLNB	8 months, no recurrence
<b>Zhang W et al (6)</b>	65/F	Left	2	Non tender mass in breast	Upper inner quadrant	Lobulated mass	Malignant tumor	WLE+SLNB	Pulmonary metastasis
<b>Suleman FE et al (7)</b>	58/F	Left	12.6	Non tender mass in breast	Upper outer quadrant	Circumscribed round mass	Organizing fat necrosis	Left sided mastectomy	Recurrence
<b>Novrial D, Yamsun M (8)</b>	45/F	Left	2	Non tender mass in breast	-	-	-	Excisional biopsy	2 years, no recurrence
<b>Terada M et al (9)</b>	74/F	Right	1.7	Tender mass in breast	Upper outer quadrant	Indistinct mass	Metaplastic breast carcinoma	Mastectomy+ SLNB	1 year, no recurrence
<b>May SA et al (12)</b>	60/F	Left	3	Non tender mass in breast	Lower quadrant	Organizing hematoma	Fat necrosis with cystic degeneration and exuberant giant cell reaction	Left mastectomy	Pulmonary metastasis

TM: Total Mastectomy, SLNB: Sentinel Lymph node biopsy, WLE: Wide lesion excision

In our case, we considered excision biopsy as a reasonable procedure followed by close follow-up, because mammography did not suggest any lymph node spread. Partial mastectomy can be acceptable, only when the tumour is localized enough to achieve complete resection. Sentinel lymph node biopsy can also be acceptable, only when breast cancer is

suspected on clinical examination and imaging. The importance of long-term clinical and radiological follow-up after resection is emphasized to detect any form of a possible recurrence early and ensure swift, concise treatment options.

## Conclusions

Primary GCT-ST arising in the breast is exceedingly rare. This tumour pretends a breast malignant tumour. For the correct diagnosis of this rare tumour, it is necessary to think of GCT-ST when coming across giant cell-rich breast lesions. Complete tumour resection should be performed for local control and the definitive diagnosis. By combining the results of histological and immunohistochemical analyses it helps in excluding differential diagnoses. Awareness of GCT of the breast is essential, and careful long-term follow-up is needed to understand the clinical course of GCT of the breast.

## Author contribution

**PJ** review of literature, article writing and corresponding author, **VP** case details and data acquisition, review of literature and article writing, **RC** review of literature and article writing, image capturing and acquisition, **VS** case details and revision of the article, **AR** revision and improvement of the article. All the authors contributed to the article and approved the submitted version.

## Conflict of interest

None declared.

## Consent

Informed written consent was obtained from the patient to publish this case report.

## Funding

There is no funding.

## References

1. Salm R, Sissons HA. Giant-cell tumours of soft tissues. *J Pathol.* 1972;107(1):27-39.
2. Sbaraglia M, Bellan E, Dei Tos AP. The 2020 WHO Classification of Soft Tissue Tumours: news and perspectives. *Pathologica.* 2021;113(2):70-84.
3. Mancini I, Righi A, Gambarotti M, et al. Phenotypic and molecular differences between giant-cell tumour of soft tissue and its bone counterpart. *Histopathology.* 2017;71(3):453-460.
4. Jadhav DS, Bagate AN, Swami SY, et al. Metaplastic carcinoma of breast-giant cell rich variant. *Indian J Cancer.* 2010;47(1):88–89.
5. Luangxay T, Osako T, Yonekura R, et al. Giant cell tumour of soft tissue of the breast: Case report with H3F3A mutation analysis and review of the literature. *Pathol Res Pract.* 2020;216(2).
6. Zhang W, Kong X, Qi Y, et al. Primary Giant Cell Tumour of the Breast with Pulmonary Metastasis: A Case Report and Review of the Literature. *Front Oncol.* 2021; 11.
7. Suleman FE, Vilakazi MN, Bida M, et al. Primary giant cell tumour of the breast with recurrence: A rare case report. *SA J Radiol.* 2022;26(1).
8. Novrial D, Yamsun M. Primary Giant Cell Tumour of Soft Tissue in The Female Breast. *Jurnal Profesi Medika: Jurnal Kedokteran dan Kesehatan.* 2022; 16(1): 79-81.
9. Terada M, Gondo N, Sawaki M, et al. A case of giant cell tumour of the breast, clinically suspected as malignant breast tumour. *Surg Case Rep.* 2019; 5:77.
10. Syed H, Edi B, Frederick K, et al. Carcinoma with metaplasia and low-grade adenosquamous carcinoma. In: *Rosen's Breast Pathology.* Philadelphia: Wolters Kluwer. 2021; 5<sup>th</sup> edition
11. Wargotz ES, Norris HJ. Metaplastic carcinomas of the breast: V. Metaplastic carcinoma with osteoclastic giant cells. *Hum Pathol.* 1990;21(11):1142–1150.
12. May SA, Deavers MT, Resetskova E, et al. Giant cell tumour of soft tissue arising in breast. *Annals of Diagnostic Pathology.* 2007; 11(5): 345-349.